


HUMANOID S

HARTWIG HAUSDORF



reserved in formaldehyde, pressed into a 16-inch-high glass, and sharing almost nothing with other examples in the collection, a horrible creature has spent the last 265 years in a little museum in Waldenburg, a small city in the German region of Saxonia. The so-called "Chicken-Man" is Germany's greatest mystery. Is it just an extraordinary miscarriage? Or do we have surprising evidence for a case of targeted genetic manipulation by extraterrestrials, abandoned when the results did not meet their expectations?

In other words: Could this exhibit be a hybrid between man and an extraterrestrial life form?

A Monstrous Birth

In the year 1735, 28-year-old housewife Johanna Sophia Schmied of Taucha, a village near Leipzig, became pregnant for the fourth time. Although she had delivered three healthy sons before, this time she gave birth to a terrifying "monster."



Dr. Gottlieb Friderici of Leipzig, who witnessed the entire event, thoughtfully preserved the creature in formaldehyde to give future colleagues the possibility of solving the uncanny mystery of the strange being. After the initial autopsy, Friderici wrote a 32-page report in Latin, which contained the medical history of the mother and meticulously reported the results of his examinations.

At the time of birth, Johanna Sophia Schmied had been married to a "hunchback." She was "of short and stocky stature and had a choleric-melancholic temper." Without a question, this cannot be the explanation for bringing forth such a monster, especially if we take a look at her older, completely healthy children.

Even the course of her fourth pregnancy was pretty unusual: According to Dr. Friderici, the fetus did not grant her belly "its due height as seen with others." The birth itself took more than seven hours.

Dr. Friderici immediately hired a draftsman at his own expense to make drawings for upcoming generations. After a brief external observation, the doctor

MONSTRVM
HVMANVM RARISSIMVM
 RECENS IN LVCEM EDITVM
 IN TABVLA
 EXHIBET
 SIMVLQVE
OBSERVATIONIBVS
PATHOLOGICIS
 ALIISQVE ILLVC PERTINENTIBVS
 BREVITER ILLUSTRAT
GOTTLIEB FRIDERICI
 PHILOS. ET MEDIC. D.

LIPSIAE
SVMTV AVCTORIS
 LITTERIS IO. CHRISTIANI LANGENHEMIL.
 CIO MDCC XXXVII.

Dr. Friderici wrote a 32-page report in Latin, which not only contained the medical history of the mother but also reported the results of his examinations. He was not able to solve the mystery, so he made it possible for future colleagues to continue his research.

chose to "neither be hesitant nor to wait any longer" and dedicated himself in his description specifically to the autopsy of the being, namely the "inner anatomy of the unhappy monster."

During this autopsy, the doctor observed anomalies from the "normal" human anatomy. The oversized, monstrous head did not present itself to be hydro-

cephalic, as the tumor-like outgrowth was completely filled with brain matter. Other anomalies were found in the lungs and the heart. The latter did not feature a heart sac (pericardium), but was embedded inside a "peculiarly thin membrane."

The inner organs of the monstrous creature were not the only anomalies. Its bone structure deviated in many charac-



Hartwig Hausdorf on the stairs of Waldenburg "Natural and Art Cabinet" with the glass case showing the mysterious creature, which has been stored there since 1735.

teristics from a normal human being. Neither the lower arms (normally consisting of the ulna and the radius) nor the lower legs (in humans, the fibula and the tibia) consisted of two bones, likewise the patella (caps) of the knees were absent.

Dr. Friderici was certainly right to have given the creature the name "monster," because neither its exterior nor interior appearance corresponded to the natural structure of a human being. There are discrepancies in number, size, and above all, certain components are entirely missing while others appear to be "extraordinarily developed."

Perplexity in a Pickle Jar

After completing his examinations, Dr. Friderici stored the creature in formaldehyde for future generations to "broaden their knowledge about such things and to multiply such and to convert such knowledge into usefulness."

In later years, the exhibit was added to the collection of the "Natural and Art Cabinet" of the city of Waldenburg in Saxonia, halfway between Glauchau and Chemnitz in Eastern Germany. During the time of the communist government in the former German Democratic Republic (DDR), the mysterious artifact was strictly prohibited from public display for reasons

that have never been made clear. The fall of the Berlin Wall brought about a change in this policy.

In the early 1990s, Dr. Dieter Mueller, chief medical doctor of the Children's Hospital in Chemnitz, visited the Waldenburg Museum and discovered the monster from the year 1735 amidst other miscarriages displayed there. Dr. Mueller initiated various examinations at the University of Heidelberg and the University of Berlin's Faculty of Medicine.

Countless X-rays have been taken of the "Chicken-Man," as the creature was now called, and a series of CAT-scans were also made. There is even talk of some genetic analysis, but not even that would put an end to this unique and mysterious case!

I have been to the Waldenburg Museum twice, first at the end of May 1997, and then again on March 8, 1998, when I came with two TV production teams, after Germany's biggest newspaper (*Bild*) had produced a major story about the case. Ralph Zenker, curator of the museum, seemed quite irritated by all of the attention the museum was getting and even threatened to prohibit our filming! His behavior was highly incomprehensible, as media interest has generated throngs of paying visitors for the small museum.

Apparent similarities exist between this

"Monstrum Rarissimum Humanum" and the little "Greys" described by people who have been abducted in CE-IV cases, which occur more and more often in today's world. These specific characteristics include:

- The eyes of the creature are extraordinarily large. When I turned the glass in my hands, I was able to see the black eyeballs shimmering through a thin membrane. The eyes are situated in unnaturally round eye-sockets.

- There are no externally visible ears present. According to the testimony of the museum staff working, the X-rays which were taken in 1994 in Heidelberg and Berlin did

show an ear canal inside the oversized skull. The little "Greys" are also described as lacking externally visible ears.

- The tumor-like outgrowth on the head is not filled with water, but with brain matter—just as Dr. Friderici diagnosed back in 1735. As I turned the glass with the creature inside, I could observe the unnaturally elongated skull which reminded me of the skull deformation practices of many tribes around the world.

An 18th-Century Abduction?

Do we possibly have the result of a historic case of abduction—or CE-IV encounter—here?

Was Johanna Sophia Schmied artificially impregnated, just as many of today's abducted women claim? And if so, why was this pregnancy carried to its "natural" completion—the birth of a hybrid, carrying the genetic characteristics of the human race along with those of an extraterrestrial intelligence, a creature not able to live on this planet? Are there any references in the records of Dr. Friderici pertaining to the possibility of such a scenario?

Indeed, a passage in the text caught my attention. There is the description that the pregnant woman had a terrifying encounter with a marten. But what does such an animal have to do with abduction sce-

rios? A number of researchers, such as professor David Jacobs, Budd Hopkins, and Whitley Strieber, describe numerous inductions during which the victims generate so-called "screen-memories," i.e., memories which mask the actual, terrifying event.

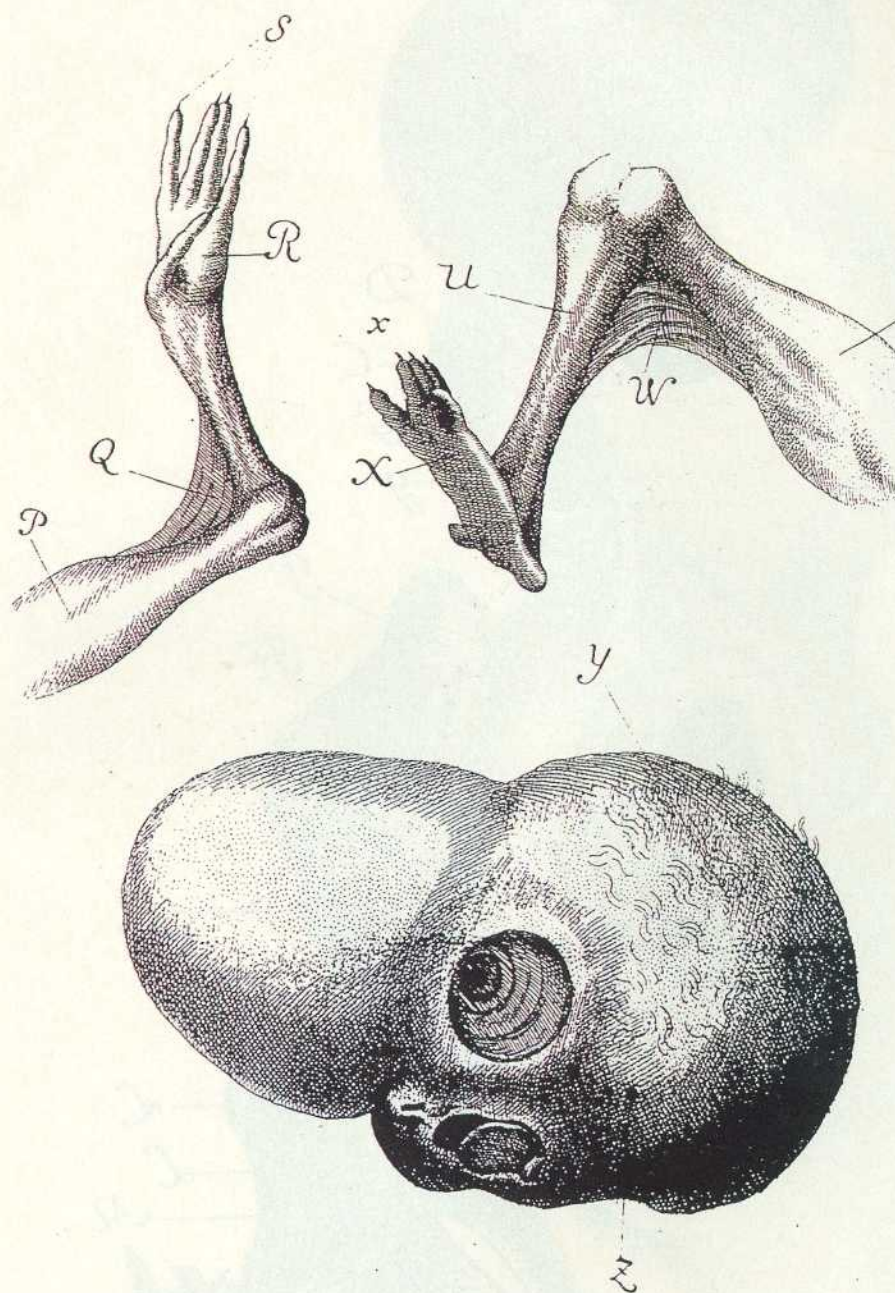
Many times these screen memories contain wild animals such as wolves, owls, deer, and even hedgehogs, which disguise the real course of events. Psychologists have found the same type of mental camouflage in traumatic crime victims, such as abused children or rape victims.

In this special case we may note that it would be rather strange for an eighteenth-century woman, who lived in a rural area, to display such immense fear of a simple marten. This, however, must have been the case—otherwise Dr. Friderici would not have considered it important to note this detail. Had this fear, in reality, been formed by a totally different cause? Was the "marten" really a symbol for an unbelievable, shocking event—the abduction and artificial impregnation of the poor woman by an extraterrestrial life form?

Dr. Johannes Fiebag (Germany's most prominent researcher on the UFO abduction subject) made an analysis of the last witch trial, against Margarete Kolbe in the year 1655, which may lend credence to the above-mentioned hypothesis. During her interrogation, Margarete Kolbe described events which could refer to an abduction by aliens and the presence of a hybrid child. Margarete Kolbe was found guilty of involvement with the devil, and was burned at the stake—a fate which, fortunately enough, did not befall Johanna Schmied of Taucha only 80 years later.

Extraterrestrial Factor

Could the "Chicken-Man" of Waldenburg possibly represent such a hybrid? During my interview on May 30, 1997, a staff member of the museum told me that even Dr. Dieter Mueller was not excluding such a possibility! Even after repeated questioning, she insisted that Dr. Mueller would "very cautiously consider an extraterrestrial factor." Letters and inquiries addressed to Dr. Mueller pertaining to this



The bone structure of the mysterious being deviates in many characteristics from a normal human individual. Neither the lower arms nor the lower legs consisted of two bones, and the patella of the knees were absent.

question remain unanswered to this day, and he has not been willing to give a television interview.

Dr. Mueller has announced that he would write an article, describing the results of genetic tests on the creature, for the

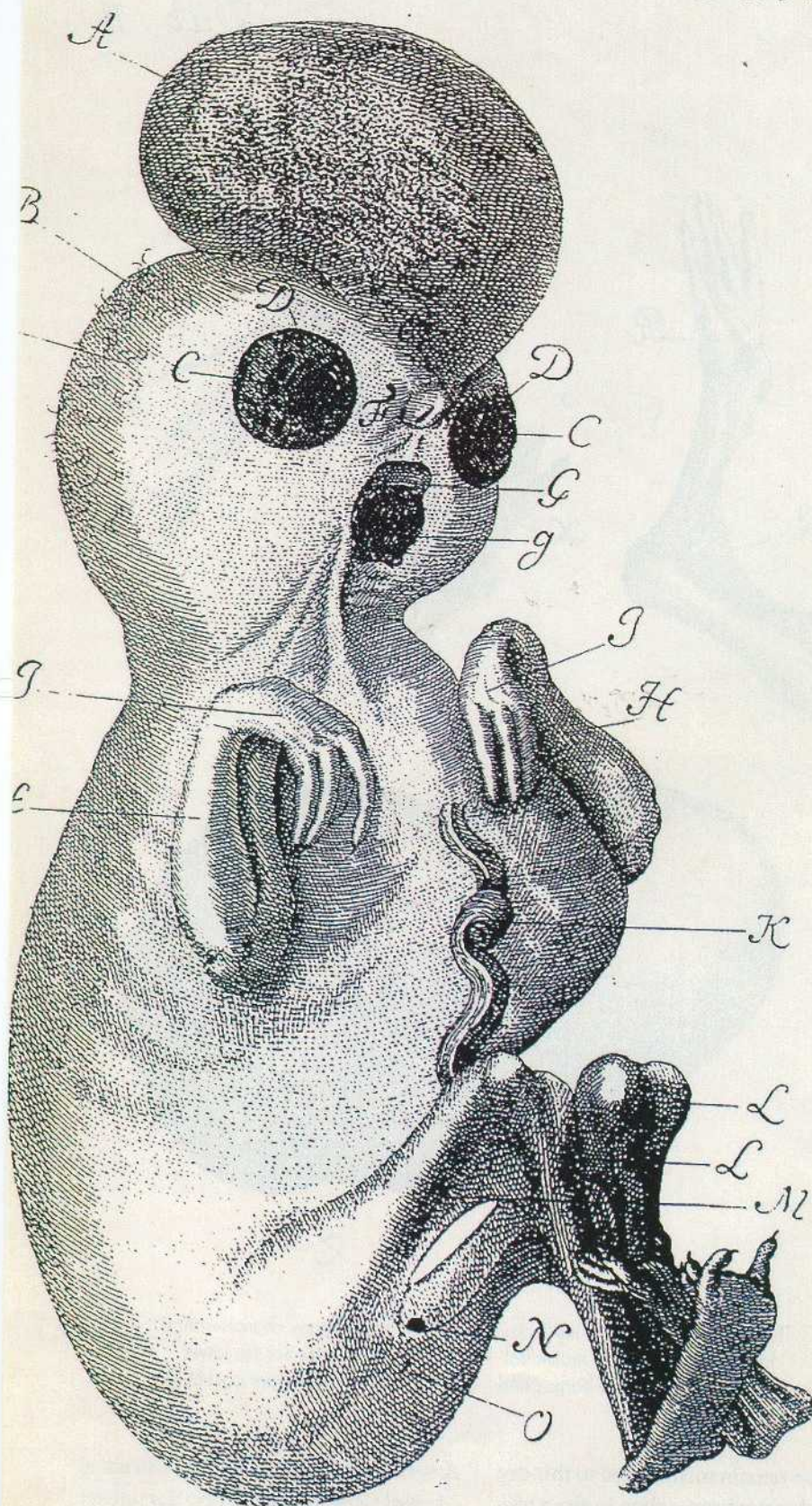
American scientific periodical *Journal of Medical Genetics*. This article has not yet been published.

Two issues are now of utmost importance:

- All results of the examinations made

HUMANOID 5

Tab: I.



in Heidelberg and Berlin must be made public. We must never allow the results of these examinations, which are ultimately being paid for by the public, to go directly into obscure secret vaults of medical schools and remain "dormant" or maybe even withheld from public access.

• In case the following has not yet been done, it is absolutely necessary for a genetic test to be conducted to determine if the "Monstrum Humanum Rarissimum" indeed contains strange genetic material.

Since the "Monstrum" has succeeded in stirring interest not only in Germany, but worldwide, I am sure that the last word on Waldenburg's dark mystery has yet to be spoken! ~

Hartwig H. Hausdorf is a renowned German author, researcher, and lecturer on unsolved phenomena. He was the first Westerner to be permitted by the Chinese authorities to enter forbidden areas containing more than 100 pyramids. Hartwig has written seven books, including *The Chinese Roswell*, and his work has been translated into 13 languages.

Star Child Update

On a similar note, we have an update from Lloyd Pye, featured in Billy Cox's article on Starchild (FATE, November 1999).

The results of Carbon 14 dating and DNA testing reveal, at least tentatively, that the Starchild skull is that of a human male of 900 years ago. This is far older than previously assumed, but the bad news is that the evidence suggests that the skull is human and not extraterrestrial.

The dating implies that the child and his mother lived during the florescence of the Aztec culture in Mexico and may be related to the oddly deformed beings who were revered by the priesthood at Cholula, a center for the worship of Quetzalcoatl.

For more information, see the postings at www.starchildproject.com.

In 1735, Dr. Gottlieb Frederici made the first autopsy of the "monster," which was brought forth by Johanna Sophia Schmied from Taucha, near Leipzig/Saxonia.